

Case Report

Resolution of diplopia after 33 years

D. Hammond^{1,*}, N. Grew² and L. Bruzual³

¹Department of Oral and Maxillofacial Surgery, Russells Hall Hospital, Dudley, West Midlands, UK, ²Department of Oral and Maxillofacial Surgery, New Cross Hospital, Wolverhampton, West Midlands, UK and ³Department of Oral and Maxillofacial Surgery, Russells Hall Hospital, Dudley, West Midlands, UK

*Correspondence address. Department of Oral and Maxillofacial Surgery, Russells Hall Hospital, Dudley, West Midlands, UK. Tel: +44-79-89-98-42-93; E-mail: d.hammond@tesco.net

Received 18 June 2013; accepted 25 June 2013

A 54-year-old male sustained a fractured right orbital floor 33 years ago, which was treated with a silastic implant. His diplopia never resolved, and he presented to us with an acute orbital cellulitis. Computerized tomography showed a displaced inferior rectus and entrapment of both inferior and medial recti. The implant was removed surgically via a Caldwell–Luc approach and his diplopia completely resolved after 33 years.

INTRODUCTION

The treatment of orbital floor fractures with silastic sheet was prominent, until the advent of the titanium plate. It was an adequate treatment; however, it had a tendency to migrate through the skin. Diplopia when present for months tends to be difficult to resolve surgically, and what makes this case unique is that diplopia has resolved after >30 years.

CASE REPORT

A 54-year-old male presented to our department with a right-sided chemosis, periorbital swelling and was systemically unwell. Clinically, his visual acuity was 6/12 in his right eye and 6/6 in his left eye. He had an obvious right enophthalmos. He reported that he had surgery on a fractured right orbit 33 years ago and had had persistent diplopia since. He had never had any infective episode previously.

He was treated with systemic and topical antibiotics. On review he reported that his diplopia had worsened, but clinically his eye and swelling was much improved. A CT scan (Fig. 1) showed: 'A 17 mm defect in his right orbital floor. A (silastic) implant was displaced, lying vertically in the saggital plane. It protrudes through the orbital defect into the medial orbit. The inferior rectus is prolapsed through the orbital floor. Inferior and medial recti are both trapped by the implant'.

A decision was made to remove the implant surgically via a Caldwell–Luc approach. This was performed successfully.

Within 4 weeks of surgery, the patient reported that his diplopia had resolved, for the first time, in 33 years. His visual acuity was 6/6 in both eyes.

The treatment of orbital floor fractures with silastic sheet is well documented and there are large case series published [1]. However, there is a high complication rate when using silastic as a material to repair orbital floor fractures. Complications include: implant migration to the skin and the maxillary sinus,

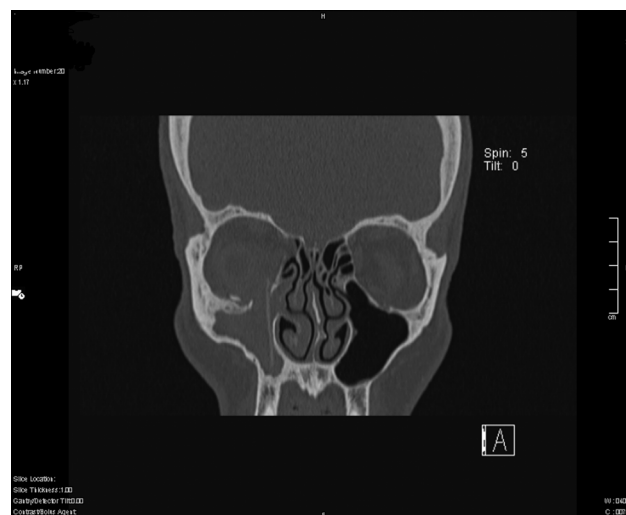


Figure 1: Coronal slice of CT scan demonstrating silastic sheet protruding through the right orbital floor.

skin fistula, persistent diplopia, communication between the orbit and the sinus, periorbital cellulitis [2]. 13.8% of patients required surgery to remove the silastic at 20 years [2].

DISCUSSION

The treatment of the fractured orbital floor has advanced over the last 30 years. Computerized tomography, custom made implants, resorbable and non-resorbable implants [3], the use of endoscopic surgery [4] and stereolithography all have an important role in the treatment of the fractured orbital floor.

Silastic complications may develop late and the latest published resolution of diplopia following surgery is 20 years [5]. We feel that our patient is fairly remarkable, in

that his diplopia has resolved at 33 years after initial surgery.

REFERENCES

1. Morrison AD, Sanderson RC, Moos KF. The use of silastic as an orbital implant for reconstruction of orbital wall defects: review of 311 cases treated over 20 years. *J Oral Maxillofac Surg* 1995;**53**:412–7.
2. Laxenaire A, Levy J, Blanchard P, Lerondeau JC, Tesnier F, Scheffer P. Complications of silastic implants used in orbital repair. *Rev Stomatol Chir Maxillofac* 1997;**98**(Suppl 1):96–7.
3. Piombino P, Iaconetta G, Ciccarelli R, Romeo A, Spinizia A, Califano L. Repair of orbital floor fractures: our experience and new technical findings. *Craniofacial trauma Reconstr* 2010;**3**:217–2.
4. Farwell DG, Strong EB. Endoscopic repair of orbital floor fractures. *Ophthalmology* 1999;**106**:1214–8.
5. Warrior S, Prabhakaran VC, Davis G, Selva D. Delayed complications of silicone implants used in orbital fracture repairs. *Orbit* 2008;**27**:147–51.