



CJC Open ■ (2021) 1–5

Case Report

A Novel Frameshift Mutation, *KCNH2* [p.Asp896ArgfsX79], Leading to Malignant Ventricular Arrhythmia, Identified After Treatment of Gastrointestinal Bleeding

Wan Cheol Kim, MD, FRCPC,^a Edmond Lemire, MD, PhD, FRCPC, FCCMG,^b
Siddarth Nosib, BSc,^c and Shrivankumar Nosib, MD, FRCPC^d

^aDepartment of Medicine, University of Dalhousie, Halifax, Nova Scotia, Canada

^bDivision of Medical Genetics, University of Saskatchewan, Royal University Hospital, Saskatoon, Saskatchewan, Canada

^cCollege of Medicine, University of Central Lancashire, Preston, United Kingdom

^dDepartment of Medicine, University of Saskatchewan, Royal University Hospital, Saskatoon, Saskatchewan, Canada

ABSTRACT

A novel frameshift mutation in the *KCNH2* gene for long QT syndrome type 2 (LQTS2) was identified after torsades des pointes ventricular tachycardia in a 49-year-old patient managed with octreotide and nadolol for an acute variceal bleed. In spite of removal of offending medications, and correction of underlying electrolyte abnormalities, the patient's QT interval remained prolonged—at 521 ms—raising the suspicion of an underlying channelopathy. Genetic studies confirmed heterozygosity for a novel frameshift mutation for the *KCNH2* gene, D896Rfs X79. We explore the pathogenicity and clinical impact of this variant mutation.

RÉSUMÉ

Une nouvelle mutation de changement de phase du gène *KCNH2* impliqué dans le syndrome du QT long de type 2 (SQT2) a été trouvée après une tachycardie ventriculaire à torsades de pointes chez un patient de 49 ans traité par octréotide et nadolol en raison d'un saignement variqueux en phase aiguë. En dépit du retrait des médicaments mis en cause et de la correction des anomalies électrolytiques sous-jacentes, l'intervalle du QT du patient qui demeurait prolongé (à 521 ms) a suscité la suspicion d'une canalopathie sous-jacente. Des études génétiques ont permis de confirmer l'hétérozygoté d'une nouvelle mutation de changement de phase du gène *KCNH2*, D896Rfs X79. Nous examinons la pathogénicité et les répercussions cliniques de cette mutation du variant.

Long QT syndrome type 2 (LQTS2) is an inherited channelopathy that results in prolongation of the QT interval that may manifest clinically as torsades des pointes ventricular tachycardia (TdP VT) and sudden cardiac death if untreated.

Almost two-thirds of the mutations of the *KCNH2* gene are missense mutations, wherein a single change in the nucleotide sequence results in a defective amino acid causing loss of function of ionic channel Kv11.1. The remaining one-third of the mutations of the *KCNH2* gene are either nonsense mutations or frameshift mutations. These mutations, by modifying protein synthesis, generate impaired alpha subunits of the Kv11.1 ionic channel.

We report a patient who presented with an acute gastrointestinal bleed, in whom therapy provoked TdP VT from

QT-prolonging drugs. Diagnostic workup unmasked a novel frameshift mutation in the *KCNH2* gene causing LQTS2. This variant mutation, D896RfsX79, has not been reported previously in the genome databases.

Case

A 49-year-old male, recently diagnosed with liver cirrhosis, presented with a 1-week history of shortness of breath and fatigue secondary to a recurrent variceal bleed. His medications included nadolol, furosemide, spironolactone, lansoprazole, and levothyroxine. His medical history included a remote mitral valve repair. He denied a history of presyncope or syncope. There was no history of sudden cardiac death in his family.

His vital signs were stable. A cardiorespiratory exam was normal. There was no evidence of chronic liver disease.

His hemoglobin was 72 g/L, with abnormal liver function tests, and he had an elevated serum creatinine level of 124 µmol/L. His admission potassium level was 4.6 mmol/L. His electrocardiogram showed a resting heart rate of 68 beats per minute, and a QTc interval of 520 ms (Fig. 1A).

Received for publication March 17, 2021. Accepted June 1, 2021.

Ethics Statement: Our research has adhered to the relevant ethical guidelines.

Corresponding author: Dr Shrivankumar Nosib, 1010 Pohorecky Bay, Saskatoon, Saskatchewan S7W 0J4, Canada. Tel.: +3067159997.

E-mail: shravan.nosib@gmail.com

See page 5 for disclosure information.

<https://doi.org/10.1016/j.cjco.2021.06.005>

2589-790X/© 2021 The Authors. Published by Elsevier Inc. on behalf of the Canadian Cardiovascular Society. This is an open access article under the CC BY-NC-ND license (<http://creativecommons.org/licenses/by-nc-nd/4.0/>).

Novel Teaching Points

- A novel frameshift mutation (cDNA: c.2684_2685 insCC; Variant:p.Asp896ArgfsX79) in the *KCNH2* gene, consistent with a genetic form of LQTS2, is identified.
- Genetic variants may modulate arrhythmic risk and may confer a higher risk of life-threatening electric events beyond traditional risk factors and in spite of normal QTc intervals.
- Cirrhosis of the liver has been associated with a prolonged QT interval, and this effect can be exacerbated by the use of inward potassium rectifier channel blockers and other medications. LQTS may be unmasked in the process.
- QT-prolonging agents enhance the arrhythmic risk of sudden cardiac death and must be avoided in this setting.

He was started on octreotide infusion (50 mcg/h) after 50 mcg IV bolus along with nadolol therapy. He received 1 unit of packed red blood cells. Gastroscopy revealed grade II varices with active bleeding, treated with banding. Post-procedure, he developed syncope and was unresponsive. He was pulseless. Telemetry showed TdP VT¹ (Supplemental Fig. S1). He was resuscitated with one cycle of cardiopulmonary resuscitation, single defibrillation, and a 2 g dose of IV magnesium sulfate. His serum magnesium level was 0.67 mmol/L. His heart rate had dipped to 47 beats per minute prior to the arrest, and it remained in the 50s post code (Fig. 2, A and B). Telemetry strips documented early premature ventricular contractions as the initiating event of the TdP VT (Fig. 1B).

He was started on isoproterenol infusion, and octreotide and nadolol were discontinued. Echocardiography showed normal left ventricular systolic function, and left heart catheterization showed normal coronaries. However, his QTc remained prolonged at 521 ms, raising the suspicion of an underlying channelopathy (Fig. 1).

A routine electrocardiogram done 5 years earlier showed a corrected QT interval of 426 ms. The patient had not been diagnosed with liver cirrhosis at the time. Genetic modulation in the setting of liver cirrhosis was thought to be unmasking QT-prolongation and possible channelopathy.

Genetics

Genetic analysis was carried out after discussion with the patient, his wife, and his daughter about possible implications in case of a positive result. The following 12 genes currently known to be associated with LQTS were screened: *KCNQ1*, *KCNH2*, *SCN5A*, *ANK2*, *KCNE1*, *KCNE2*, *KCNJ2*, *CACNA1C*, *CAV3*, *SCN4B*, *AKAP9*, and *SNTA1*. The patient was found to be heterozygous for a frameshift mutation in the *KCNH2* gene for LQTS2 syndrome, with insertion of 2 cytosines in the genomic sequence (c.2684_2685insCC) leading to a premature stop codon at position 79 of the new reading frame (p.Asp896ArgfsX79), potentially explaining his prolonged QT interval. This mutation causes a shift in the reading frame starting at codon Aspartic acid 896 and changing it to an Arginine. As a class 1 mutation, it is expected to result in either an abnormal, truncated protein

product or loss of protein from this allele through nonsense-mediated RNA decay. At the molecular level, the pore domain of the alpha subunit of the inward potassium rectifier channel (Ikr) channel is affected, specifically transmembrane segments S5-S6 which contribute to the pore domain.

The full transcript of the mutation is: c.2684_2685insCC:p.Asp896ArgfsX79(D896RfsX79) in exon 11 of the *KCNH2* gene (NM_000238.2) (Supplemental Fig. S2). The normal sequence with the bases that are inserted in braces is: GCAC{CC}GCAC. The mutation is not reported in major variant databases.

The patient's only daughter declined screening, and family screening could not be performed, as the patient was a first-generation immigrant from India.

Management

He was offered an implantable cardioverter-defibrillator (ICD) for secondary prevention, but he declined this therapy. However, he agreed to proceed with a permanent pacemaker implantation to prevent further episodes of bradycardia.

Discussion

This case highlights the unique challenges of managing acute gastrointestinal bleeding with beta-blockers and octreotide in the setting of undiagnosed LQTS. Both pharmacologic agents likely caused his bradycardia, which is a known trigger for TdP VT in the setting of a prolonged QT interval. In fact, the patient suffered a "perfect-storm" scenario, with cirrhosis, a known QT-prolonging condition, electrolyte abnormalities, and acute illness.

QT-prolonging agents should be discontinued. It is optimal to keep potassium levels between 4.5 and 5 mmol/L.² Beta-blockers are recommended in those with LQTS with prolonged QT, and in those who have had cardiac events.³ Our patient was on nadolol, which, although intended for treatment of portal hypertension, had failed to prevent syncope, TdP, and pulseless VT during acute illness characterized by bradycardia and electrolyte abnormalities. This phenomenon is not uncommon, as one previous study noted that LQTS2 carriers, despite being on beta-blocker therapy, had higher rates of cardiac events compared to those with LQTS1 (23% vs 10% over a 5-year period).⁴

In high-risk patients in whom beta-blockade is ineffective or not tolerated, ICD therapy and/or left cardiac sympathetic denervation (LCSD) is indicated per guidelines. There is a marked reduction in the incidence of arrhythmic sudden cardiac death after LCSD; however, in high-risk patients with LQTS, recurrent lethal electric events have been reported in up to 50%.¹ LCSD is not an alternative to ICD, but rather, is complementary to it.

Approximately 20 years ago, it was found⁵ that one of the long QT-causing genes was mapped to chromosome 7. Later, it was determined that the *KCNH2* (or *HERG*) gene codes for a potassium channel that facilitates the rapid component of the delayed outward-rectifying potassium current responsible for generating a QT interval.⁶ Numerous mutations in this gene have since been reported and are thought to be responsible for the prolonged QT interval that causes LQTS2. The mutation found in our case

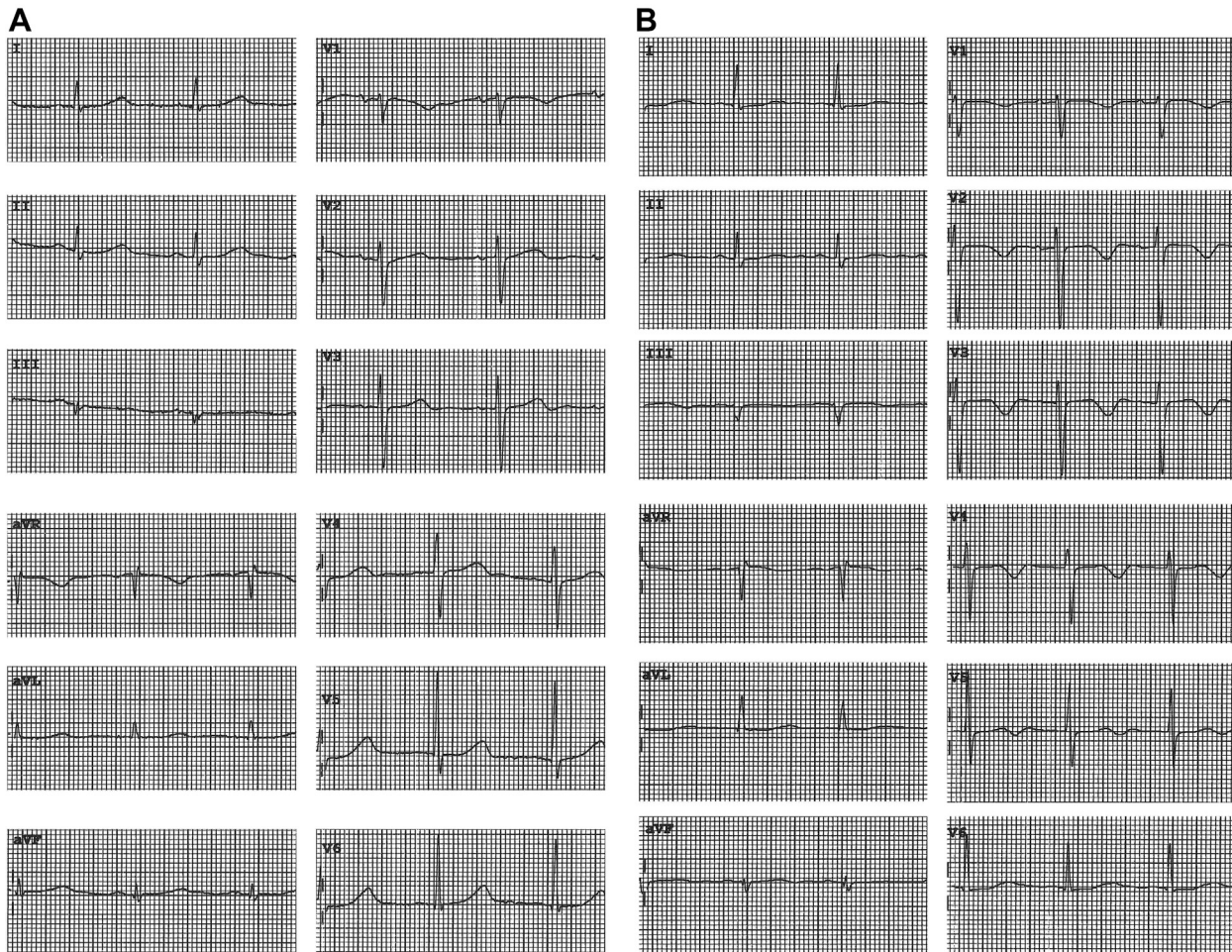


Figure 1. Electrocardiogram of a patient with congenital long QT syndrome type 2. (A) Patient was receiving octreotide infusion and nadolol for variceal bleeding. QTc interval is ~ 520 ms. (B) Taken 60 hours after torsade des pointes and monomorphic ventricular tachycardia. Despite correcting hypomagnesemia and bradycardia through isoproterenol infusion, a prolonged QTc interval (~ 520 ms) persists, indicating an increased likelihood of congenital long QT syndrome. Evidence of macrovolt T wave alternans shows in precordial leads.

(c.2684_2685insCC) generates a premature termination codon at position 79 of the new reading frame (p.Asp896ArgfxX79) and is expected to result in a defective channel that clinically prolongs the QT interval. Resulting haploinsufficiency causes a milder phenotype, as only about 50% of the Kv11.1 channels lose their function, while the remaining ones function normally, which may explain the fact that our proband was asymptomatic prior to presentation. Other frameshift mutations in the *KCNH2* gene have been reported in the human gene mutation database.⁷ More recently, Yoo et al. have reported a novel *KCNH2* frameshift mutation (c.46delG) in a family with congenital LQTS2.¹ There was a high incidence of sudden cardiac death in this family, and repeated syncopal spells in the proband; thus, it was phenotypically very different from the proband reported in our case.

An important fact to note is that not all truncating variants have been labeled as pathogenic. Clinvar reports 59 nonsense variants for *KCNH2*, of which 51 are pathogenic, 4 are likely benign, 6 are likely pathogenic, and 1 has uncertain status. Frameshift variants, as identified in our patient, also often end

up in a downstream truncation. Clinvar identifies 187 of these—148 are pathogenic, 8 have uncertain status, 1 is likely benign, and 5 have been given conflicting interpretations.

Experimental evidence for truncating variants has been reported by De Zio et al. in an Italian family in which the proband suffered recurrent episodes of ventricular fibrillation arrest despite a QTc interval of < 500 ms, as well as a C terminally-located mutation of the *KCNH2* gene, both of which are predictive of a more benign course.^{Supplemental Ref S1} However, Moss et al. have demonstrated that patients with mutations exerting a dominant-negative functional effect were more susceptible to arrhythmic events, independent of clinical risk factors—namely, QTc duration, beta-blockade, and gender.^{Supplemental Ref S2}

Thus, in our patient, the dominant-negative effect of the variant on the *Ikr* channel subunits over the wild-type *KCNH2* channel subunits may explain the pathogenicity of the mutation, in spite of the previously documented normal QTc of 426 ms and a previously benign cardiac history.

The prevalence of LQTS has been a controversial topic, and it is noteworthy that Schwartz et al. had suggested in 1975 that

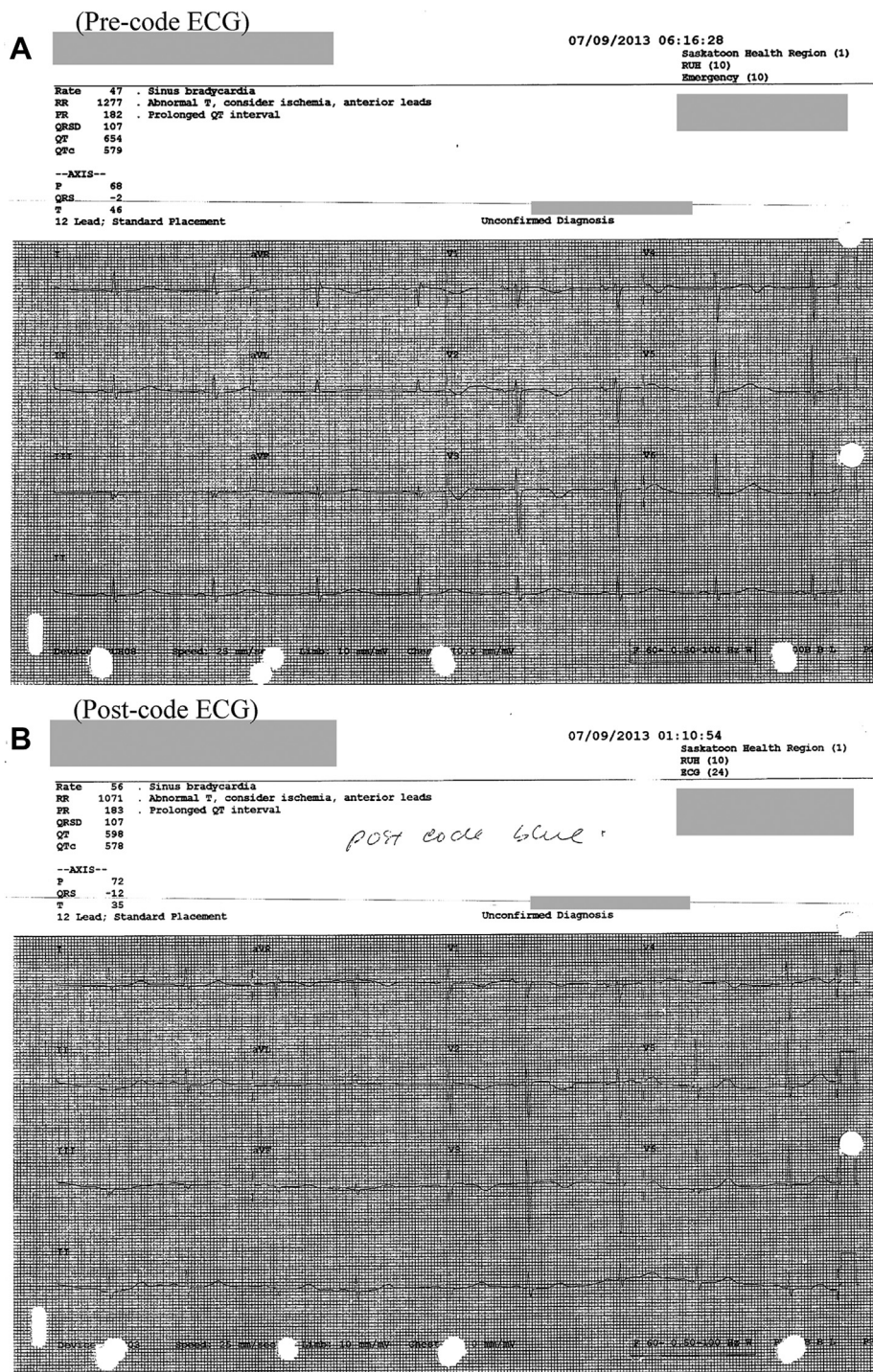


Figure 2. (A) Pre-code electrocardiogram (ECG) showing heart rate of 47 beats per minute and a QTc interval of 579 ms. (B) Post-code ECG showing heart rate of 57 beats per minute and a QTc interval of 578 ms.

“LQTS is more unrecognized than rare.”^{Supplemental Ref S3} In fact, the prevalence of silent mutations is high in LQT1 patients (36%), moderate in LQT2 patients (17%), and lower in LQT3 patients (10%). Thus, undiagnosed LQTS may be a challenging public health issue that needs further probing to identify new LQTS2 patients before they suffer life-threatening electric events.

Conclusion

Our case report describes a patient presenting with QT-prolongation and TdP ventricular tachycardia following a variceal bleed, in whom a heterozygous frameshift mutation resulting in a premature stop codon was identified in the *KCNH2* gene. The use of Ikr blockers uncovered the LQTS2 phenotype and enhanced the risk of TdP VT in this patient.

Funding Sources

The authors have no funding sources to declare.

Disclosures

The authors have no conflicts of interest to disclose.

References

1. Yoo HS, Medina N, Von Wulffen MA, et al. A novel *KCNH2* frameshift mutation (c.46delG) associated with high risk of sudden death in a family with congenital LQTS type 2. *Int J Arrhythm* 2021;22:1.
2. Drew BJ, Ackerman MJ, Funk M, et al. Prevention of torsade de pointes in hospital settings: a scientific statement from the American Heart Association and the American College of Cardiology Foundation. *J Am Coll Cardiol* 2010;55:934-47.
3. Zipes DP, Camm AJ, Borggrefe M, et al. ACC/AHA/ESC 2006 guidelines for management of patients with ventricular arrhythmias and the prevention of sudden cardiac death. *J Am Coll Cardiol* 2006;48:e247-346.
4. Priori SG, Napolitano C, Schwartz PJ, et al. Association of long QT syndrome loci and cardiac events among patients treated with b-blockers. *JAMA* 2004;292:1341-4.
5. Jiang C, Atkinson D, Towbin JA, et al. Two long QT syndrome loci map to chromosomes 3 and 7 with evidence for further heterogeneity. *Nat Genet* 1994;8:141-7.
6. Curran ME, Splawski I, Timothy KW, et al. A molecular basis for cardiac arrhythmia: HERG mutations cause long QT syndrome. *Cell* 1995;80:795-803.
7. Stenson PD, Mort M, Ball EV, et al. The human gene mutation database: 2008 update. *Genome Med* 2009;1:13.

Supplementary Material

To access the supplementary material accompanying this article, visit *CJC Open* at <https://www.cjopen.ca/> and at <https://doi.org/10.1016/j.cjco.2021.06.005>.