

Assessing Mandibular Nerve Injury Risk in Orthograde Endodontic Treatment

Allen Gaon BDS MSc (Endo) MFDS RCPS(Glasg) MDTFEd MFDS RCSEd MFGDP(UK)
Private Practice, Amersham, Buckinghamshire

Paul Cruci BDS MSc (Endo) MSc (Imp Dent) MFDS RCPS(Glasg) MFDS RCSEd FDSRCSEd MDTFEd DPDS
MGDSRCS MFGDP LDSRCS
Specialist in Endodontics, Gerrards Cross, Buckinghamshire

StJohn Crean BDS MBBS FDSRCS FFGDP(UK) FDSRCPS (Glasg) FRCS FRCS(OMFS)PhD PGCMed Ed (Camb) LLM
(Edin) FHEA
Pro Vice Chancellor (Research, Innovation and Enterprise), Professor of Medicine in Dentistry, Consultant Oral
and Maxillofacial Surgeon University of Central Lancashire

Jackie Brown BDS MSc FDSRCPS DRRRCR
Consultant in Dental & Maxillofacial Radiology KCL Faculty of Dentistry, Oral & Craniofacial Sciences at Guy's &
St Thomas' NHS Foundation Trust

John Rout BDS MDentSci FDSRCS(Eng) DRRRCR
Consultant in Dental & Maxillofacial Radiology KCL Faculty of Dentistry, Oral & Craniofacial Sciences at Guy's &
St Thomas' NHS Foundation Trust

Overview

In this article we hope to describe the problem of nerve injury associated with endodontic treatment; a relatively rare but significant risk.

Specifically, the article will propose guidance and recommendations on how risk and morbidity can be reduced by reviewing anatomical, pathological and procedural factors. (See Table 3)

The role of 2 and 3D radiography in case assessment will be reviewed with reference to:

1. Anatomical factors
2. The effects of pathological change at the apex and in the peri-apical tissues
3. Decision making with regards to referral for specialist advice and/or care

We propose a new, simple to use 3-Tier grading system based upon radiographic and clinical assessment to aid risk assessment and thus decision-making regarding suitability for treatment, the need for further investigation, management and/or referral. This grading system will assist dentists to fully apprise patients and gain appropriate informed consent in advance of treatment. (See Table 1)

Introduction

Nerve injury is a relatively uncommon but nonetheless serious side effect of endodontic treatment of mandibular posterior teeth (Pogrel, 2017; Rosen, 2017). It can result in permanently altered sensation which can have serious effects on the patient's quality of life (Smith *et al.*, 2013). It is largely avoidable with correct preoperative assessment and treatment protocols.

Inferior alveolar and mental nerve injuries are most commonly (but not exclusively) reported in relation to mandibular second molars and premolars. An understandable desire to retain teeth coupled with complex restorative histories increasingly presents practitioners with challenging endodontic cases which may involve greater risk of nerve damage.

Incidence of mandibular post endodontic nerve injuries

The literature contains significant references to persistent altered inferior alveolar nerve sensation resulting from the administration of local anaesthesia. Whilst the authors recognise this as an important cause of nerve injury, we feel the subject lies outwith the scope of this article.

Most reports of post-endodontic nerve injuries are case studies. Knowles *et al* investigated paraesthesia related to endodontic treatment of 832 mandibular premolars, reporting an incidence of 0.96% (Knowles *et al.*, 2003).

Klasser *et al* found a 7% incidence of chronic neuropathic pain among 2338 patients having undergone a single endodontic procedure (Klasser *et al.*, 2011).

Pogrel reported on a series of 61 patients over a 7-year period with endodontic sealer extruded into the inferior alveolar canal (IAC) (Pogrel, 2017). Six of the cases exhibited radiographic evidence of sealer in the IAC but were asymptomatic. The author hypothesized that the lack of symptoms may have been due to relatively low neurotoxicity of the sealer and/or lack of penetration of the epineurium.

In 42 cases, there was evidence of sealer or obturation material in the IAC, but either symptoms were mild or too great a time delay was judged to have elapsed for surgical treatment to be likely to succeed. Fewer than 10% of these cases experienced resolution of symptoms.

Classification of nerve injury was described by Seddon in and Sunderland (Seddon, 1943). The least severe injury in which nerve integrity is retained but where signalling ability is temporarily impaired is termed **neuropraxia**. Partial damage to the axon (which may recover in 2-12 months) is termed **axonotmesis**. Extensive damage to the full axon thickness and associated connective tissue is termed **neurotmesis**.

The clinical effect of these lesions may be categorised as **paraesthesia**- sensory disturbance resulting in (for example) sensations such as burning or partial numbness. **Hypoaesthesia** refers to a state of reduced sensitivity to stimulation. **Hyperaesthesia** describes a sensation of heightened sensitivity to stimulation. **Anaesthesia** refers to complete insensitivity to

stimulation. These states tend to be dynamic, frequently changing over time following the nerve injury.

Sources of nerve injury related to endodontic intervention

Direct Trauma:

This may result from over-instrumentation with hand or rotary instruments, irrigating cannulas or overextension of chemically inert obturation materials. Where obturation materials are heated prior to condensation, additional thermal trauma may result.

Over-instrumentation is best avoided by careful preoperative assessment including radiographic length estimation using 2 or 3-D modalities as required. The routine use of an electronic apex locator (EAL) should be considered obligatory for any orthograde endodontic procedure.

Chemical trauma:

Extra-radicular extrusion of Sodium Hypochlorite (NaOCl) solution can result in severe damage to neural tissue due to its high pH and powerful action in breaking down fatty and amino acids.

The trend toward using more concentrated NaOCl solutions as endodontic irrigants may potentiate this effect. Grossman and Meiman observed that the speed of dissolution of pulp fragments was directly proportional to NaOCl solution concentration (Grossman & Meiman, 1941). They also found that the greater the initial concentration of NaOCl, the smaller the reduction in pH following contact with pulp tissue.

Neurapraxia of infective origin:

Periapical lesions near the inferior alveolar nerve (IAN) can cause pressure injuries due to local oedema and associated inflammatory mediators such as Interleukin1, Tumour Necrosis Factor and Nitric Oxide have neurotoxic potential owing to their low pH. Bacteria and their by-products may also produce chemically mediated neural effects (Devine *et al.*, 2017).

There is currently no protocol for management of such injuries, nor is much known about the potential for recovery, especially in the case of longer standing lesions. Schultze-Mosgau *et al* suggest that the potential for sensory recovery after several months is low (Schultze-Mosgau & Reich, 1993).

It is important that the practitioner preoperatively recognises the existence of neuropathy in relation to a periapical lesion or acute infection. Part of the patient history in assessment of a mandibular posterior tooth should therefore include enquiry as to any sensory changes in the distribution of the IAN.

The potential for development of acute infection especially following the initial stages of endodontic treatment means that consent documents should recognise and include reference to the possibility of sensory alteration or loss as a result of treatment.

Anatomical proximity of the IAC relative to root apices:

Bürklein et al examined 626 CBCT scans of male and female subjects to investigate the shortest distance between the IAC and the root apices of second premolars, first, second and third molars. A total of 1974 teeth were included (Bürklein *et al.*, 2015). Mean distances were 4.2, 4.9, 3.1 and 2.6mm respectively. These distances were significantly shorter in women than men.

Importantly, the study also identified a direct relationship between root apices and the IAC in 3.2%, 2.9%, 15.2% and 31.3% of teeth, respectively. Such a communication was seen almost twice as frequently in women than men.

In addition, significantly shorter distances from the IAC to root apices were seen in patients aged under 35 years compared with older patients.

Thus, caution is warranted when planning endodontic treatment of mandibular second and third molars in younger female patients as apices are frequently not only closer to the canal but also more often directly communicating with it.

Bifurcation of the IAC:

Shah et al (2018) in a CBCT study of 281 patients, identified a 38% incidence of IAC bifurcation. Some patients had multiple bifurcations.

Bifurcation was most commonly found posterior to the third molar or within 2mm of the third molar roots. The study also found that the sensitivity of panoramic radiography in detecting canal bifurcation was poor.

Most bifurcations ran in a superior direction in the same plane as the main canal, with smaller proportions running in superobuccal and superolingual directions.

Therefore, in advance of undertaking an endodontic procedure with the potential for IAN damage, it is critical to determine the true location of the IAC in respect to the periapical anatomy.

Traditionally, dentists relied on 2-D images drawn from periapical intraoral radiographs taken, at best, with a paralleling technique. This methodology provided some general comfort if the classical IAC "tramlines" or more accurately the corticated canal borders were evidenced to be distant from tooth apices.

However, the process is technique sensitive and relies on correct positioning of the intra oral film/sensor relative to the target area and X ray tube. Often this is not achieved and leads to angular foreshortening/lengthening.

Additionally, superimposition of local bony anatomy e.g., external oblique ridge can often lead to further misrepresentation.

Inability to clearly visualise the IAC does not exclude it from risk of damage.

Traditionally, when considering preoperative radiographs (usually DPTs) for the extraction of lower wisdom teeth a series of classic radiographic appearances were used to assess proximity of a tooth to the IAC:

- a) Change of density (radiolucency) of the root
- b) Loss of lamina dura around the root where it is crossed by the canal
- c) Constriction or narrowing of the root
- d) Curvature or hooking of the root where it abuts up against the roof of the canal
- e) Change in direction of the canal as it crosses the root
- f) Loss of one or both of the cortical outlines (tramlines) of the canal
- g) Constriction or narrowing of the canal

(Rood & Shehab, 1990)

Using these interpretations in an endodontic scenario may help to provide useful guidance in determining risk of damage to the IAC.

2-D imaging is a first line approach when determining risk, but any doubt arising should warn the operator to consider the follow up use of 3-D imaging to determine the precise spatial relationship of the periapex and the topography of the IAC.

A low volume, high definition CBCT scan will reveal the spatial relationship between teeth and vital structures. It will also help to provide information regarding root canal morphology and any aberrations (including unexplored canals, calcifications, previous treatments) and importantly the visualisation of the degree of any apical resorption. This may well be challenging or missed entirely 2-D image. Additionally, the integrity of the mandibular lingual cortical plate and relative proximity of molar apices to it will also be shown

Preparation and length control in the apical 1/3 of the root canal is vital in limiting the placement of intermediate dressings, sealer and obturation material length. This is particularly important in the management of apical resorption cases or with teeth with intrinsic irregularly shaped and wide apical orifices or those created by the infective process or iatrogenic handling.

It is important to visualise that roots within a spongy bone milieu characterised by a cancellous bone of various density sandwiched by a buccal and lingual cortical plate. The shape and structure of the bony trabeculae and medullary spaces or vacuoles can easily allow tracking of hydraulically extruded material well beyond the physiological terminus of the root towards the IAC. A sparse trabecular pattern is common in the posterior mandible and may increase the risk of an extension of an hydraulic sealer extrusion. A list of potential causes for reduced alveolar bone density has been listed in Table 4.

The cortical integrity of the IAC is also not uniform. Where there is a reduced or intermittent cortication there is a greater likelihood for iatrogenic damage. CBCT analysis is useful in enabling practitioners to determine the bony topography.

As described above, mechanical pressure and ischemia related to a periapical inflammatory process can exert pressure on both the Mental nerve (MN) and the IDN. The size of the infection, degree of resorption and tissue destruction and the proximity of the source to the IDN or MN directly correlates to the risk of neural damage. Hence, measures should be taken to alleviate primary infection and periapical pressure at the earliest opportunity, particularly in cases where a neuropathic history has been elicited.

Instrumentation and procedural considerations:

The IAN can be irreversibly damaged by direct trauma from over instrumentation. Repair of the damaged tissue and can lead to scarring but this may still lead to temporary paraesthesia. (Grossman & Meiman, 1941; Rowe, 1983)

Over preparation can also lead to disruption of the natural architecture of the apical terminus which can encourage diffusion of irrigation solutions, intermediate dressings and medicaments into the periapical area and therefore close to or into the IAC (JH *et al.*, 1999). Without a well-constructed apical capture zone, the final obturation material will also be unstable and may extrude into the periapical region leading to a potential chemical and mechanical neuropathy.

Practical Considerations:

1. Never rely on the "feel" of reaching the apical constriction as a means of length determination
2. The use of a calibrated EAL to determine position of physical terminus is mandatory
3. Instrument 0.5-1.0mm from the EAL zero reading.
4. Use of the EAL in a "live fashion" whilst instrumenting the terminal 1mm of the canal, ensuring that a direct relationship exists between file insertion/withdrawal and corresponding changes in EAL readings. This indicates that the unit is likely to be functioning correctly.
5. Minimal or no patency filing in cases when the IAC is intimately placed to the root apex (0.25mm max push-pull with continuous application of EAL)

Irrigation:

Although the use of NaOCl has been questioned when irrigating canals of lower molars, it is still considered the gold standard irrigant in endodontics. Consideration must be given to dissolution/disinfection of necrotic and infected material in the root canal lumen.

Alternative irrigants do not possess the dual qualities of tissue dissolution and disinfection. Therefore, sacrificing the effectiveness of root canal cleaning would seem ill advised if there is a risk of persistent infection. Great care must be taken to ensure any irrigant always remains in the canal lumen and does not extrude under pressure as this may cause local tissue necrosis due to its caustic nature.

Practical Considerations:

1. Consider use of reduced strength NaOCl in high risk cases
2. Use of Luer-Lock side venting irrigating cannulea (30 gauge)
3. Cannula to be placed without any binding to a maximum of 3 mm of the WL.
4. Minimal digital pressure. Maintain up/down movement of cannula at all times during delivery to avoid locking in canal and pressure spike
5. The use of passive, ultrasonic or sonic irrigation (-5mm from the measured root apex)
6. Alternative use of carefully controlled “cone pumping” to ensure effective irrigant exchange in the apical ½ without the risk of extrusion.
7. Avoid use of engine driven Lentulo spiral devices
8. Careful introduction of intermediate dressings using length-controlled files.

The over instrumentation of and the use of apical patency filing carries the further risk of inoculating the periapical tissue with potentially infected material. The extrusion of this material has been reported as having the potential to breach the protective perineurium of the IAN leading to structural damage of the epineurium.

Clearly, when embarking on endodontic treatment it is essential to determine as accurately as possible where the root canal terminates and where the periapical tissues start. The apical terminus can be reliably determined by using a calibrated EAL. The authors consider this an essential tool in all orthograde endodontic treatments.

The use of a radiographic working length measurement assessment has been shown to be inaccurate and can lead to over preparation in many cases (Vieyra *et al.*, 2010). Therefore, an accurate, reproducible, and “live” linear feedback regarding instrument tip position is mandatory when approaching the canal terminus to ensure precision in preparation. Caution is required to ensure the accuracy of the EAL readings by controlling excessive moisture, using appropriately sized files, limiting cross conduction across metals e.g., clamps and metallic restorations and the conductivity of caulking materials.

Intermediate Dressings:

The uncontrolled placement of intermediate dressings can lead to extrusion and morbidity if contact with neural tissue occurs. As discussed, extrusion of material can have both chemical and compressive effects on the periapical tissues which in turn can lead to temporary or permanent changes in adjacent neural tissue

The ideal pH of an endodontic medicament or sealer should approximate to that of body fluids (circa 7.3) otherwise there is a risk of neural toxicity caused by the chemical insult in the event of extrusion. It is useful to note the pH values of the following common intracanal medicaments:

Formocresol pH 12.4, Calcium Hydroxide pH 10–14, Ledermix pH 8.13, Eugenol pH 4.34, Iodoform paste pH 2.90 (Renton, T, 2010).

Obturation:

Obturation materials including sealers should be confined to the root canal and various tributaries and should not extend to the periapical tissues or neighbouring structures (Poveda *et al.*, 2006). Although minor extrusions – traditionally known as “sealer puffs”, are

generally well tolerated, in dependent high-risk areas they must be minimised by appropriate apical capture design and hydraulic control.

Gutta percha is the most commonly used obturation material that has stood the test of time (Pascon & Spångberg, 1990). It is composed of 20% gutta-percha, 60%–70% zinc oxide, plasticizing agents (waxes and resins), barium sulphate, colouring agents and trace metals. In the presence of bone, extruded GP generally deforms favourably preventing significant compression and the risk of a mechanically induced paraesthesia. Fortunately, gutta percha also has no or low relative cytotoxicity and does not contribute significantly to chemical trauma (Tilotta-Yasukawa *et al.*, 2006). Rather it tends to be the cause of a chronic inflammatory reaction in the tissues. Therefore, GP cones are generally well tolerated beyond the apex and are rarely the cause of a chemically induced paraesthesia (Khabbaz & Papadopoulos, 1999). Notwithstanding this, extruded gutta percha may suggest incomplete preparation, disinfection and apical capture design with potential longer-term consequences from endodontic failure. Clearly, the potential for any contact with neural tissue must be recognised and addressed at the earliest opportunity. (Escoda-Francoli *et al.*, 2007; F *et al.*, 2006; Pogrel, 2007)

Root canal sealers and can be the cause of paraesthesia via chemical trauma (Dahl, 2005). Zinc Oxide and Eugenol sealers are ever popular, and the chief cause of toxicity is the eugenol component (Khabbaz & Papadopoulos, 1999; Poveda *et al.*, 2006). It has been shown that the application of Eugenol on neural tissue can irreversibly diminish conductivity within 3 hours (Kozam, 1977; Trowbridge *et al.*, 1982).

Similarly, Calcium Hydroxide sealers can have irreversible effects when exposed to neural tissue (Yatsuhashi *et al.*, 2003). A large extrusion of Ca(OH)₂ sealer in the periapical tissues was found not only to have a chemical effect but a mechano-compressive effect on the IAN leading to paraesthesia (Ahlgren *et al.*, 2003).

Thermal trauma by virtue of overheating the IAN can be caused by the extrusion of warm GP and sealer into the IAC following the injudicious and uncontrolled down pack technique (warm vertical condensation) (Blanas *et al.*, 2004). Bone and neural tissue is particularly vulnerable to thermal insult (Fanibunda *et al.*, 1998) and temperature changes of approximately +10 degrees centigrade can lead to irreversible bone damage and tissue necrosis (Eriksson & Albrektsson, 1983).

Conclusion:

As can be seen, there are many risks related to root canal over preparation and material extrusion that may lead to neural damage. As will be seen later the treatment and management of such eventualities can be distressing, onerous and challenging for both the patient and operator.

Therefore, planning and preparation with judicious execution of the treatment will help to mitigate many of the problems that we have encountered above and reduce the risk of postoperative morbidity.

We are guided in radiation safety by the principle of “ALARA”. The question arises regarding the relatively low threshold chosen to expose the patient to a scan.

It is the belief of the authors that in *these* specific cases, where the risk of morbidity is recognised, the extra and measurable information provided in 3D by exposing a small volume, high definition CBCT can provide valuable clinical information over and above that of single or multiple PAs or a DPT.

DRAFT

Table 1

The Tier Structure:

Pre-endodontic assessment of lower 1st & 2nd premolars and lower 2nd & 3rd molars

Tier 1

Assessment based on diagnostic quality 2-D Intra Oral or Extra Oral Radiographic Image - (Periapical Radiograph (PA) via paralleling technique) or Dental Panoramic Tomogram (DPT)

All findings on PA or DPT required to qualify for Tier 1, If not move to Tier 2.

Superior border of IAC, MC or MF is clearly defined

Superior border of IAC, MC or MF is >5mm from the apex/apices of the treatment tooth

If present, closest margin of periapical radiolucency is > 2mm from the IAN, MC or MF

If present, periapical radiolucency margin is well defined +/- corticated

No apical resorption evidenced radiographically

Note:

In case of bifid IAC architecture: NO radiographic changes to root as described by Rood & Shehab's

Consider treatment in General Practice

Tier 2

Assessment based on CBCT scan (small volume, high-definition scan – see Table 2 for suggested prescription)

All findings on CBCT required to qualify for Tier 2, if not move to Tier 3

The Superior Border of the IAC, MC or MF is well defined and shows complete cortication

The Superior Border of the IAC, MC or MF is <5mm but >3mm from the apex /apices of the treatment tooth

If present, closest margin of periapical radiolucency is >2mm from the IAN, MC or MF

If present, periapical radiolucency margin is well defined +/- corticated

No Apical resorption present: Apical constriction remaining intact

Note: an inferior positioned IAC (as compared to laterally placed canal) carries a higher risk if an extrusion occurs due to the more direct pathway from the apical foramen to the IAC)

A low-density trabecular pattern with large intertrabecular spaces reduces the resistance to hydraulic extrusion)

Seek Specialist guidance and/or proceed with caution

Tier 3

Only 1 CBCT finding required to qualify for Tier 3.

The superior border of the IAC, MC or MF is poorly defined or shows incomplete cortication

The superior border of the IAC, MC or MF is <3mm from the apex/apices of the treatment tooth

If present, closest margin of periapical radiolucency is <2mm from the the IAN, MC or MF

If present, periapical radiolucency has poorly defined margin

Apical resorption is present: Apical constriction lost

Advanced case – consider Specialist referral

“Traffic Light” Decision making Flow Chart

Tier 1	Radiographic Investigation: PA and/or DPT		
1	Superior border of IAC, MC or MF is clearly defined	If Yes go to 2	If No go to 6
2	Superior border of IAC, MC or MF is >5mm from the apex/apices of the treatment tooth	If Yes go to 3	If No go to 6
3	If present, closest margin of periapical radiolucency is > 2mm from the IAN, MC or MF	If Yes go to 4	If No go to 6
4	If present, periapical radiolucency margin is well defined +/- corticated	If Yes go to 5	If No go to 6
5	No apical resorption evidenced radiographically	If all Yes, consider treatment in General Practice	If No go to 6
Tier 2	Radiographic Investigation: Small Volume High Def CBCT		
6	The Superior Border of the IAC, MC or MF is well defined and shows complete cortication	If Yes go to 7	If no go to 11
7	The Superior Border of the IAC, MC or MF is <5mm but >3mm from the apex /apices of the treatment tooth	If Yes go to 8	If no go to 11
8	If present, closest margin of periapical radiolucency is >2mm from the IAN, MC or MF	If Yes go to 9	If no go to 11
9	If present, periapical radiolucency margin is well defined +/- corticated	If Yes go to 10	If no go to 11
10	No Apical resorption present: Apical constriction remaining intact	If all Yes, seek specialist advice and/or proceed with caution	If no go to 11
Tier 3	Radiographic Investigation: Small Volume High Def CBCT		
11	The superior border of the IAC, MC or MF is poorly defined or shows incomplete cortication	If Yes - consider Specialist referral	
12	The superior border of the IAC, MC or MF is <3mm from the apex/apices of the treatment tooth	If Yes - consider Specialist referral	
13	If present, closest margin of periapical radiolucency is <2mm from the the IAN, MC or MF	If Yes - consider Specialist referral	
14	If present, periapical radiolucency has poorly defined margin	If Yes - consider Specialist referral	
15	Apical resorption is present: Apical constriction lost	If Yes - consider Specialist referral	

Table 2

Suggested CBCT prescription:

Request: Small volume, High definition CBCT of the treatment tooth. with radiology report with specific mention of:

IAC/MC pathway & MF position and anatomical variants (e.g.: bifidity, anterior loop)

Spatial position and proximity of IAC/ MC/ MF to the apices of treatment tooth

Identify any IAC bifurcations

Quality/integrity of bony cortication of the IAC/MC/MF in the vicinity of the treatment tooth

Relative density of the local trabecular pattern and ratio of intertrabecular spaces, presence of sclerosis

Periapical/ root resorptive pattern

Root canal anatomy including lateral canal anatomy

Proximity of the roots to the lingual plate and mylohyoid attachment and effects of inflammatory disease on adjacent cortical plates (determination of submandibular space infection risk)

Table 3

Risk factors for nerve injury in endodontics

Anatomical factors

Proximity of IDC or MC to apex of treatment tooth
Root shape and apical curvature (eg: towards or away from ID canal)
Apical foramen patency / maturity of apical canal
Integrity of cortical outline of IDC/MC

Pathological (disease-related) factors

Size of area of apical bone destruction
Quality of bony margins of apical lesion (poorly defined / well defined /corticated)
Distance between edge of apical lesion and IDC / MC
Root resorption and changes to aperture of apical foramen
Infective and inflammatory mediators impacting on the IDN/MN

Operational factors

Instrumentation

Direct mechanical trauma (e.g.: instrument through apex, impacting on canal)
Indirect trauma/instrumentation effects (e.g.: over-instrumenting of apex)

Chemical trauma

Irrigants: e.g., Sodium Hypochlorite, EDTA, Chlorhexidine, Citric Acid, Hypochlorous acid, Iodine, Alcohol
Other medicaments, sealants, root filling materials
Local anaesthetic

Thermal trauma

Warm Vertical Compaction (Continuous & interrupted wave)
Warm Thermoplastic carrier techniques
Thermomechanical Compaction – McSpadden technique

Table 4

Potential causes for reduced alveolar bone density:

Idiopathic and natural anatomical variation
Osteoporosis
Osteopenia
Hypophosphatasia
Postmenopausal women
Hypophosphatemia
Hyperparathyroidism
Papillon-Lefèvre syndrome
Histiocytosis X
Agranulocytosis
Leukocyte adherence deficiency
Neutropenia
Leukaemia
Diabetes Mellitus
Scleroderma
Fibrous dysplasia (only in very early stages)
Acrodynia
Down syndrome
Chédiak-Higashi syndrome
Thalassemia
Sickle Cell disease

DRAFT

Case Studies:

Tier 1

Case 1:

Tooth Lower Left 2nd Molar

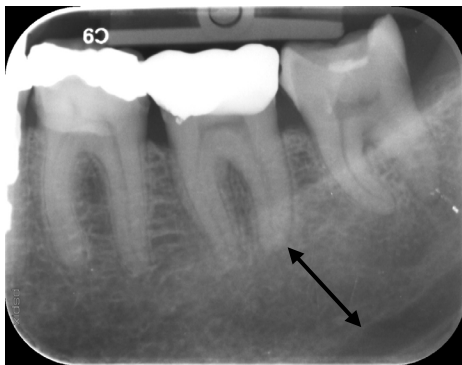
Diagnosis: Pulpal: Reversible Pulpitis (RP), Apical: Normal

The patient attended with short lived thermal sensitivity consistent with RP. The tooth is being monitored.

Superior border of IAC, MC or MF is clearly defined

Superior border of IAC, MC or MF is >5mm from the apex/apices of the treatment tooth

No apical resorption evidenced radiographically



Case 2:

Tooth: Lower Left 1st Molar

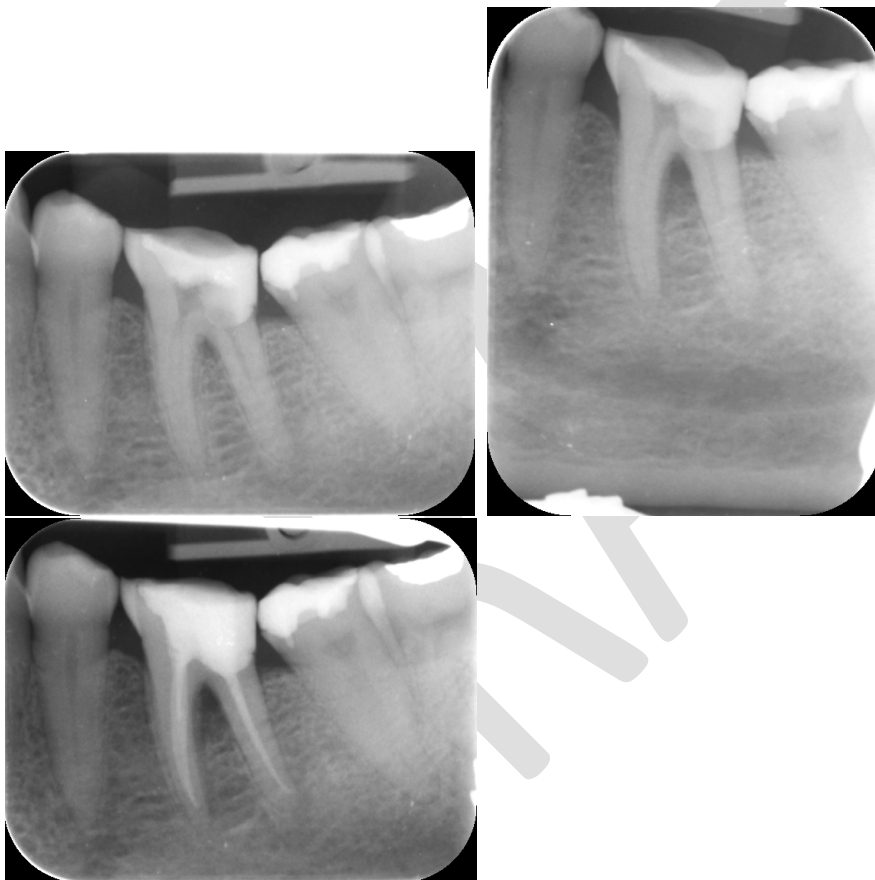
Diagnosis: Pulpal: Necrotic, Apical: Symptomatic Apical Periodontitis

Note the vertically placed Periapical Radiograph view demonstrating the position of the IDC distant from the apex of the tooth.

Superior border of IAC, MC or MF is clearly defined

Superior border of IAC, MC or MF is >5mm from the apex/apices of the treatment tooth

No apical resorption evidenced radiographically



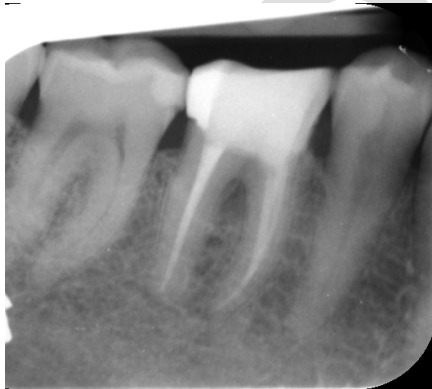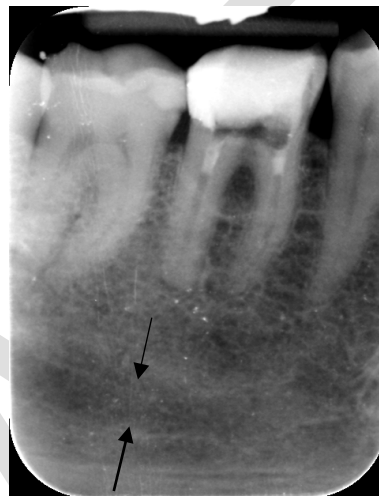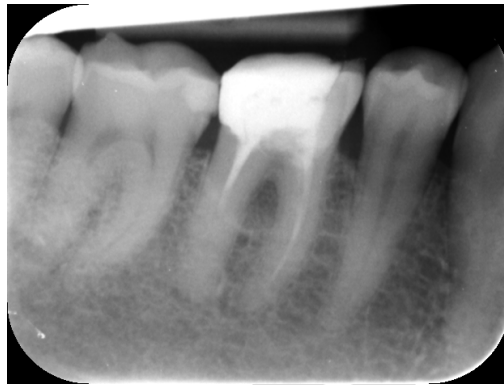Case 3:

Tooth: Lower right 1st Molar

Diagnosis: Pulpal: Previously Treated, Apical: Asymptomatic Apical Periodontitis

Note the vertically placed Periapical Radiograph view demonstrating the low position of the IDC

Superior border of IAC, MC or MF is clearly defined
Superior border of IAC, MC or MF is >5mm from the apex/apices of the treatment tooth
No apical resorption evidenced radiographically



Tier 2

Case 4

Tooth: Lower right 1st Molar

Diagnosis: Pulpal: Necrotic, Apical: Symptomatic Apical Periodontitis

The use of image enhancing software and magnification clearly identified the pathway of the IDC. In this case, a CBCT revealed a superior accessory branch of the IDC below distal root of 36.

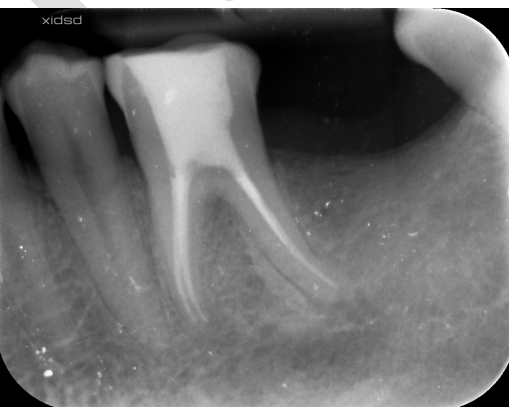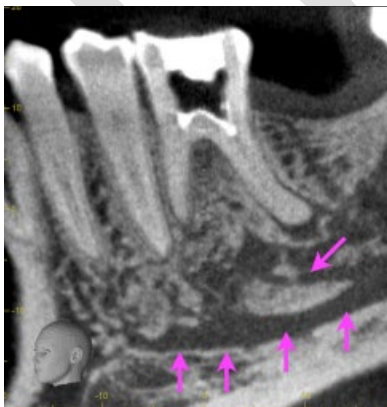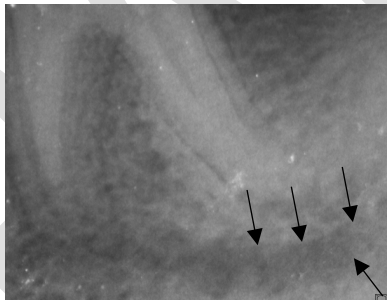
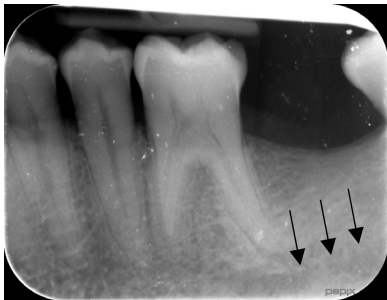The Superior Border of the IAC, MC or MF is well defined and shows complete cortication

The Superior Border of the IAC, MC or MF is <5mm but >3mm from the apex /apices of the treatment tooth

Closest margin of periapical radiolucency is >2mm from the IAN, MC or MF

Periapical radiolucency margin is well defined +/- corticated

No Apical resorption present: Apical constriction remaining intact



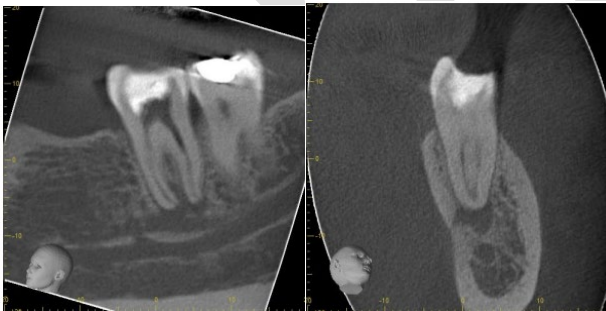
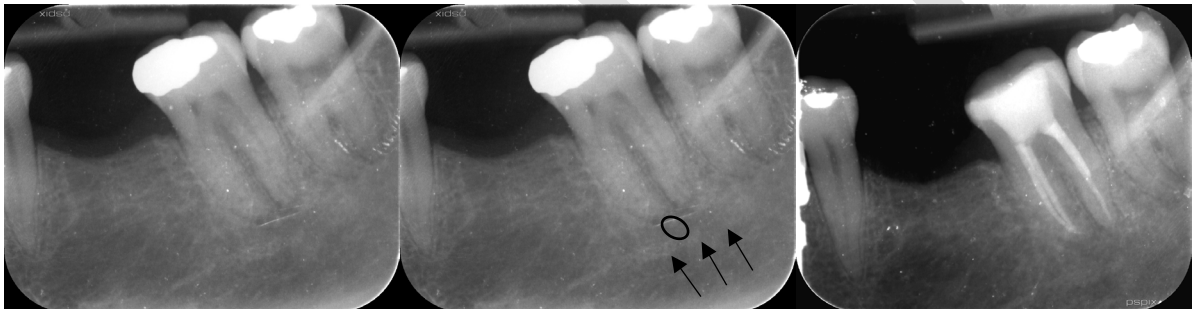
Case 5:

Lower Left 2nd Molar:

Diagnosis: Pulpal: Necrotic, Apical: Symptomatic Apical Periodontitis

The upper border of the IDC and the periapical lucency has been highlighted. Note the interspace of bone between the periapical lesion and the IDC identified on the CBCT.

The Superior Border of the IAC, MC or MF is well defined and shows complete cortication
The Superior Border of the IAC, MC or MF is <5mm but >3mm from the apex /apices of the treatment tooth
Closest margin of periapical radiolucency is >2mm from the IAN, MC or MF
Periapical radiolucency margin is well defined +/- corticated
No Apical resorption present: Apical constriction remaining intact



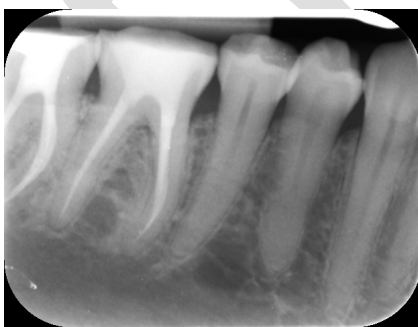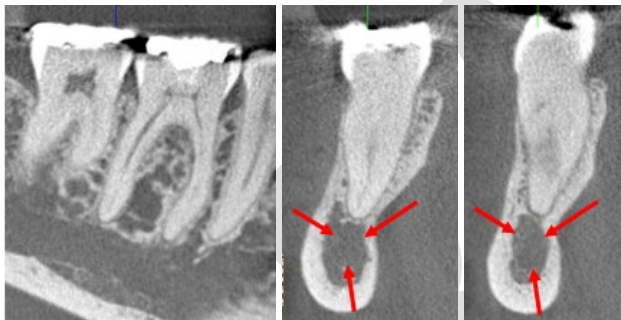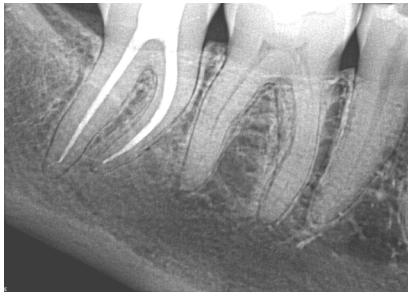
Tier 3

Case 6

Tooth: Lower Right 1st Molar

Diagnosis: Pulpal: Symptomatic Irreversible Pulpitis, Apical: Normal

The IDC has been marked. Note the reduced bone density and enlarged IDC diameter. This patient has osteopenia.

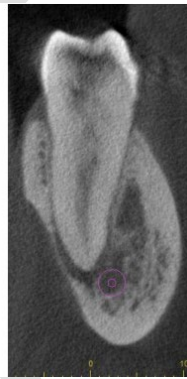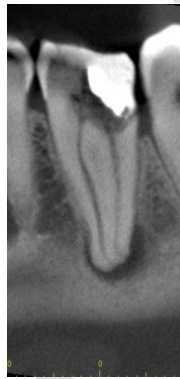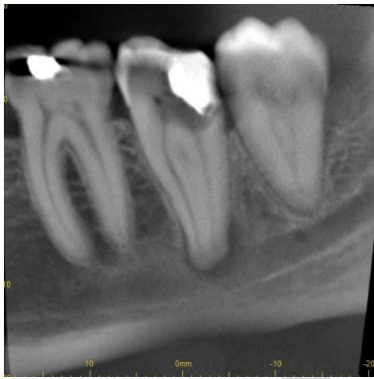


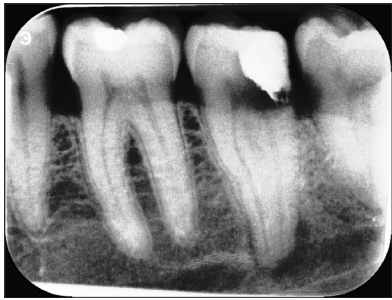Case 7

Tooth: Lower left 2nd Molar

Diagnosis: Pulpal: Necrotic, Apical: Symptomatic Apical Periodontitis

Note the close proximity of the IDC and the apical foramen. Note also the thin lingual plate and risk for progressive submandibular space infection. The patient elected to have this tooth removed.



References:

Ahlgren, F. K., Johannessen, A. C. & Hellem, S. (2003) Displaced calcium hydroxide paste causing inferior alveolar nerve paraesthesia: report of a case. *Oral Surg Oral Med Oral Pathol Oral Radiol Endod*, 96 (6): 734-737.

Whaites, T. (2020) Elsevier: *Whaites and Drage: Dental Radiology and Radiography* Â· Welcome.

Blanas, N., Kienle, F. & Sándor, G. K. (2004) Inferior alveolar nerve injury caused by thermoplastic gutta-percha overextension. *J Can Dent Assoc*, 70 (6): 384-387.

Bürklein, S., Grund, C. & Schäfer, E. (2015) Relationship between Root Apices and the Mandibular Canal: A Cone-beam Computed Tomographic Analysis in a German Population. *Journal of endodontics*, 41

Dahl, J. E. (2005) Toxicity of endodontic filling materials. *Endodontic Topics*, 12 (1): 39-43.

Devine, M., Modgill, O. & Renton, T. (2017) Mandibular division trigeminal nerve injuries following primary endodontic treatment. A case series. *Australian Endodontic Journal*, 43 (2): 56-65.

Eriksson, A. R. & Albrektsson, T. (1983) Temperature threshold levels for heat-induced bone tissue injury: a vital-microscopic study in the rabbit. *J Prosthet Dent*, 50 (1): 101-107.

Escoda-Francoli, J., Canalda-Sahli, C., Soler, A., Figueiredo, R. & Gay-Escoda, C. (2007) Inferior alveolar nerve damage because of overextended endodontic material: a problem of sealer cement biocompatibility? *J Endod*, 33 (12): 1484-1489.

Fanibunda, K., Whitworth, J. & Steele, J. (1998) The management of thermomechanically compacted gutta percha extrusion in the inferior dental canal. *British Dental Journal*, 184 (7): 330-332.

Grossman, L. I. & Meiman, B. W. (1941) Solution of Pulp Tissue by Chemical Agents. *The Journal of the American Dental Association*, 28 (2): 223-225.

Gutiérrez, JH. (1999) Human teeth with periapical pathosis after overinstrumentation and overfilling of the root canals: a scanning electron microscopic study. *International endodontic journal*, 32 (1):

Khabbaz, M. G. & Papadopoulos, P. D. (1999) Deposition of calcified tissue around an overextended gutta-percha cone: case report. *Int Endod J*, 32 (3): 232-235.

Klasser, G. D., Kugelmann, A. M., Villines, D. & Johnson, B. R. (2011) The prevalence of persistent pain after nonsurgical root canal treatment. *Quintessence Int*, 42 (3): 259-269.

Knowles, K., Jergenson, M. & Howard, J. (2003) Paresthesia Associated with Endodontic Treatment of Mandibular Premolars. *Journal of endodontics*, 29 768-770.

Kozam, G. (1977) The effect of eugenol on nerve transmission. *Oral Surgery, Oral Medicine, Oral Pathology*, 44 (5): 799-805.

Malamed, S. (2020) *Handbook of Local Anesthesia - 6th Edition*. 248-249.

Pascon, E. A. & Spångberg, L. S. (1990) In vitro cytotoxicity of root canal filling materials: 1. Gutta-percha. *J Endod*, 16 (9): 429-433.

Pogrel, M. A. (2007) Damage to the inferior alveolar nerve as the result of root canal therapy. *J Am Dent Assoc*, 138 (1): 65-69.

Pogrel, M. A. (2017) Nerve damage in dentistry. *Gen Dent*, 65 (2): 34-41.

Poveda, R., Bagán, J. V., Fernández, J. M. & Sanchis, J. M. (2006) Mental nerve paresthesia associated with endodontic paste within the mandibular canal: report of a case. *Oral Surg Oral Med Oral Pathol Oral Radiol Endod*, 102 (5): e46-49.

Rosen, E. (2017) The diagnosis and management of nerve injury during endodontic treatment. *Evidence-Based Endodontics*, 2 (1): 7.

Rowe, A. H. (1983) Damage to the inferior dental nerve during or following endodontic treatment. *British Dental Journal*, 155 (9): 306-307.

Schultze-Mosgau, S. & Reich, R. H. (1993) Assessment of inferior alveolar and lingual nerve disturbances after dentoalveolar surgery, and of recovery of sensitivity. *Int J Oral Maxillofac Surg*, 22 (4): 214-217.

Seddon, H. J. (1943) Three types of nerve injury. *Brain*, 66 (4): 237-288.

Smith, J. G., Elias, L. A., Yilmaz, Z., Barker, S., Shah, K., Shah, S. & Renton, T. (2013) The Psychosocial and Affective Burden of Posttraumatic Neuropathy Following Injuries to the Trigeminal Nerve. *Journal of Orofacial Pain*, 27 (4): 293-303.

Renton, T. (2010) Prevention of iatrogenic inferior alveolar nerve injuries in relation to dental procedures. *Dental update*, 37 (6):

Rood, J. P. & Shehab, B. A. (1990) The radiological prediction of inferior alveolar nerve injury during third molar surgery. *Br J Oral Maxillofac Surg*, 28 (1): 20-25.

Tilotta-Yasukawa, F., Millot, S., El Haddioui, A., Bravetti, P. & Gaudy, J. F. (2006) Labiomandibular paresthesia caused by endodontic treatment: an anatomic and clinical study. *Oral Surg Oral Med Oral Pathol Oral Radiol Endod*, 102 (4): e47-59.

Trowbridge, H., Edwall, L. & Panopoulos, P. (1982) Effect of zinc oxide-eugenol and calcium hydroxide on intradental nerve activity. *J Endod*, 8 (9): 403-406.

Yatsuhashi, T., Nakagawa, K., Matsumoto, M., Kasahara, M., Igarashi, T., Ichinohe, T. & Kaneko, Y. (2003) Inferior alveolar nerve paresthesia relieved by microscopic endodontic treatment. *Bull Tokyo Dent Coll*, 44 (4): 209-212.

Rood, J. P. & Shehab, B. A. (1990) The radiological prediction of inferior alveolar nerve injury during third molar surgery. *Br J Oral Maxillofac Surg*, 28 (1): 20-25.

Scolozzi, P., Lombardi, T. & Jaques, B. (2004) Successful inferior alveolar nerve decompression for dysesthesia following endodontic treatment: Report of 4 cases treated by mandibular sagittal osteotomy. *Oral surgery, oral medicine, oral pathology, oral radiology, and endodontics*, 97 625-631.

Vieyra, J. P., Acosta, J. & Mondaca, J. M. (2010) Comparison of working length determination with radiographs and two electronic apex locators. *International Endodontic Journal*, 43 (1): 16-20.